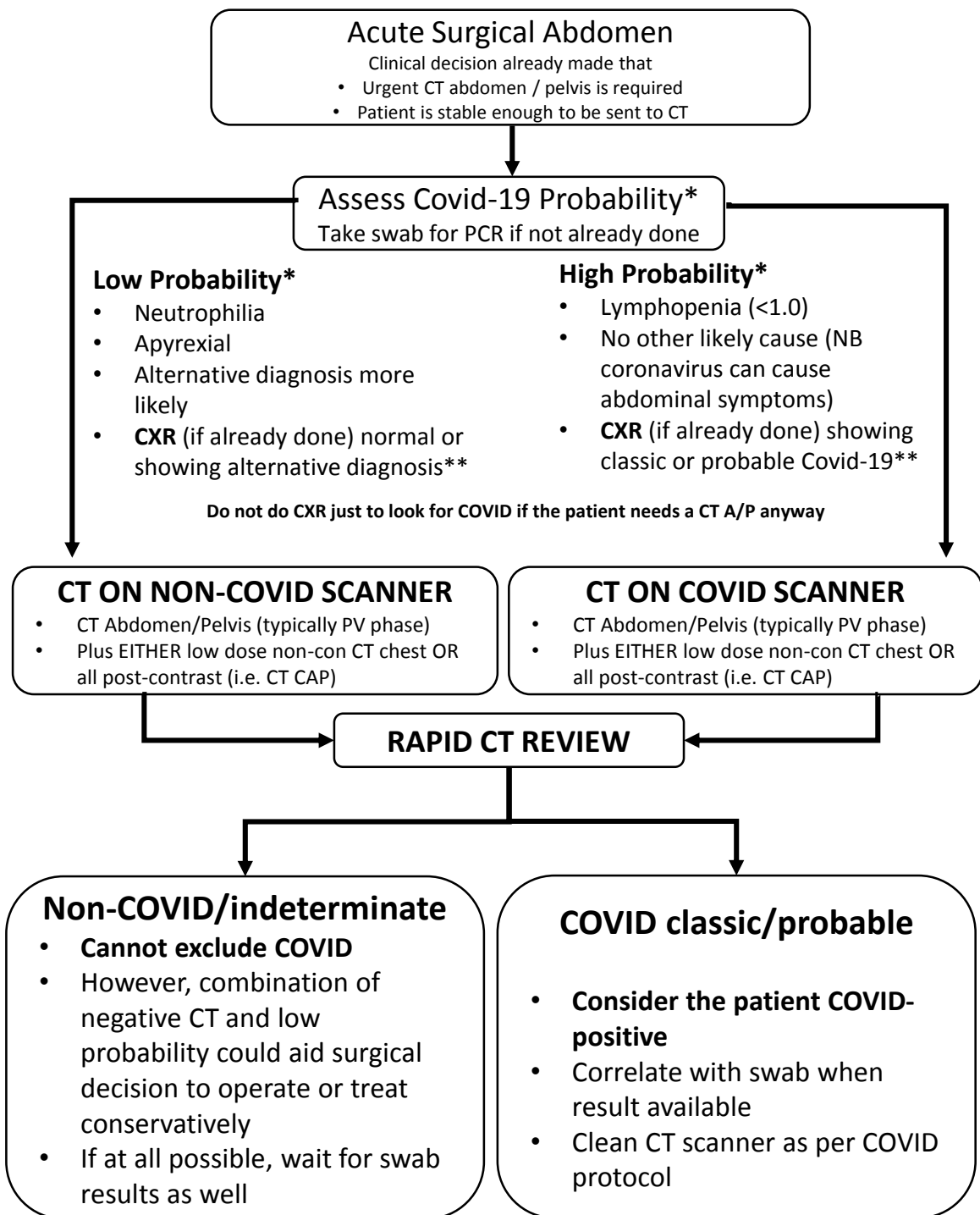


# Covid-19: BSTI/BSGAR decision tool for chest imaging in patients undergoing CT for acute surgical abdomen



\*Probability assessment as per PHE & local guidance

\*\*In some cases the patient may have already had a CXR, and this could help guide COVID probability assessment as per the BSTI/NHSE radiology decision tool. See <https://www.bsti.org.uk/covid-19-resources/>. If no CXR has been performed, as per NELA guidance we would suggest going straight to CT.

# Rationale for the tool

- In the patient with an acute abdomen requiring potential emergency surgical intervention, intubation and ventilation could be aerosol-generating.
- Reports are also emerging of increased mortality in Covid-19 positive patients in the setting of the acute surgical abdomen. As such, it may be useful to offer increased diagnostic confidence for Covid-19 in this setting, as it may influence the timing and approach to surgery.
- CT may help identify patients with Covid-19 before swab results are available; its sensitivity relative to RT-PCR has been quoted as 97% in **high risk patients with respiratory symptoms**. Although this is almost certainly an overestimate, a CT suspicious for Covid-19 in the emergency acute abdomen setting could be taken to suggest Covid-19.
- CT is only 54% sensitive in **asymptomatic patients** who are RT-PCR positive for SARS-nCOV-2 (Inui et al, Radiology Cardiothoracic Imaging March 2020 <https://doi.org/10.1148/ryct.2020200110>); as such, a negative CT **cannot be considered to have sufficient negative predictive value to exclude Covid-19**. However, in the emergency acute abdomen setting, a negative CT as well as low probability of Covid-19 could aid the confidence in the surgical decision to take the patient to theatre or manage the patient conservatively.
- As such, we advocate CT thorax (entire chest) opportunistically, if the clinical decision has already been made to send the patient for CT abdomen and pelvis, assuming cardiovascular and pulmonary stability.
- We stress that this recommendation **does not apply** to patients in whom abdominal CT (or MRI) is being performed for other reasons, or electively.
- We would recommend against extending the abdominal scan to only the caudal half of the thorax for two reasons: (1) an abnormality may be detected at the cranial-most aspect of the chest acquisition, leading to uncertainty; (2) although it would be rare for Covid-19 pulmonary findings to be solely located in the cranial half of the thorax, this is reported.
- We also suggest that rapid review by the acute reporting radiologist (ideally on the scanner table, if feasible) is obtained, to help guide probability of Covid-19 with respect to cleaning the scanners and directing the patient's subsequent disposition (Covid vs non-Covid bays).